

# Kounis Syndrome: A Case of Anaphylactic Acute Coronary Syndrome

Molly Whittaker, MD<sup>1</sup>; Thomas Wool, DO<sup>2</sup>; Adrian Messerli, MD<sup>2</sup>

<sup>1</sup>Department of Internal Medicine, University of Kentucky; <sup>2</sup>Gill Heart and Vascular Institute, University of Kentucky



## Introduction

Vancomycin is a commonly used antibiotic which is associated with many adverse reactions. In rare instances, it has been known to precipitate myocardial ischemia.

Kounis syndrome refers to myocardial ischemia secondary to hypersensitivity-induced coronary vasospasm, mediated by cardiac mast cell activation.

Diagnosis can be challenging, but distinction from typical acute coronary syndrome is important as treatment varies significantly.

Learning points for this case presentation include recognition, pathophysiology, and management of Kounis Syndrome.

## Case Presentation

A 50-year-old male with cellulitis developed chest pain, hypotension, and transient ST elevation on ECG after receiving intravenous vancomycin.

His vancomycin was stopped, and he received a 1-liter intravenous fluid bolus, diphenhydramine, and epinephrine with improvement in blood pressure and chest pain.

A repeat ECG revealed normal ST segments, and coronary angiography had no evidence of obstructive coronary artery disease.

He received daptomycin and returned home without further events.

## Evaluation

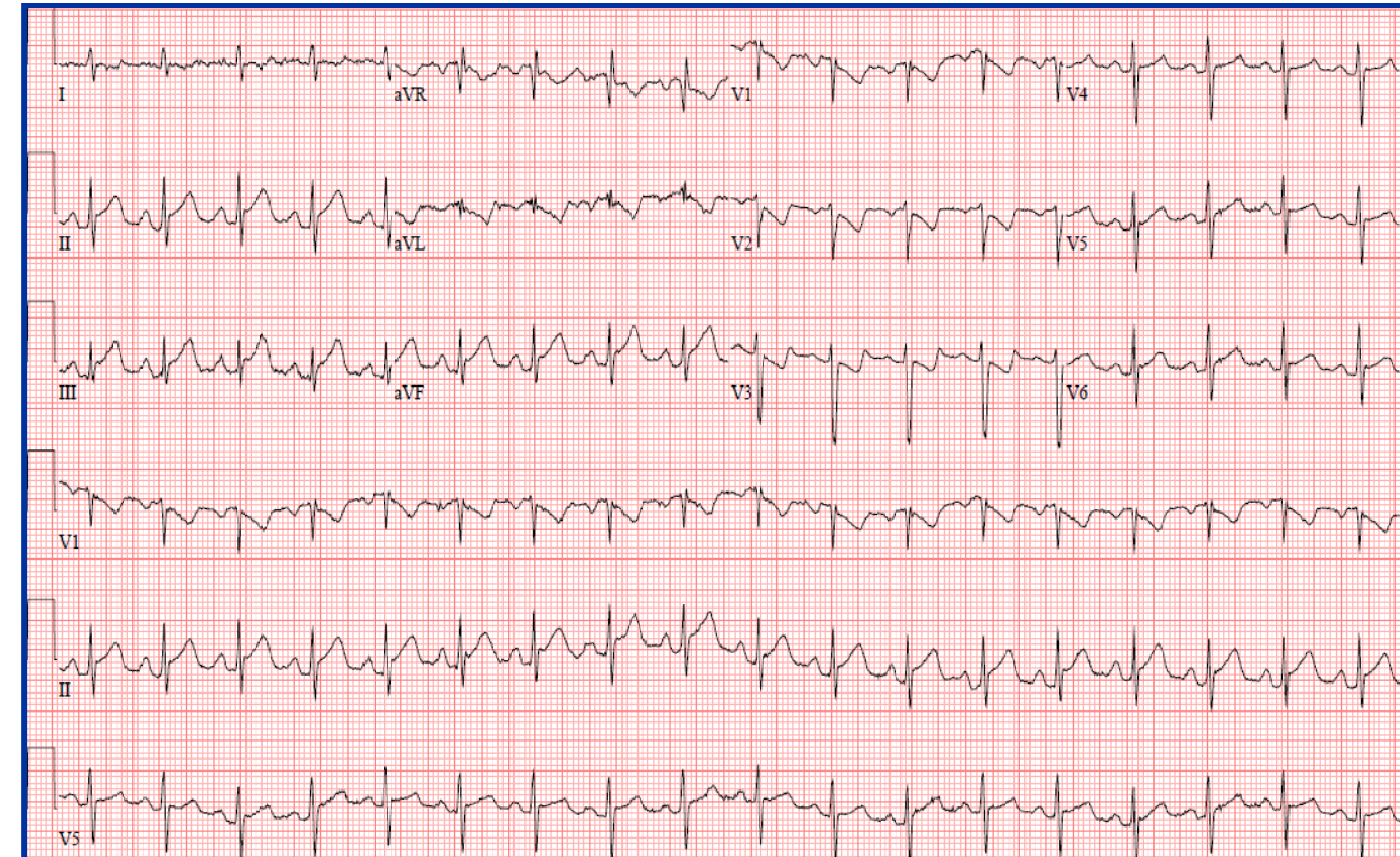
**Initial ECG:** sinus tachycardia with inferior ST elevation and anterolateral ST depression

**Repeat ECG:** normal sinus rhythm, no ischemic changes

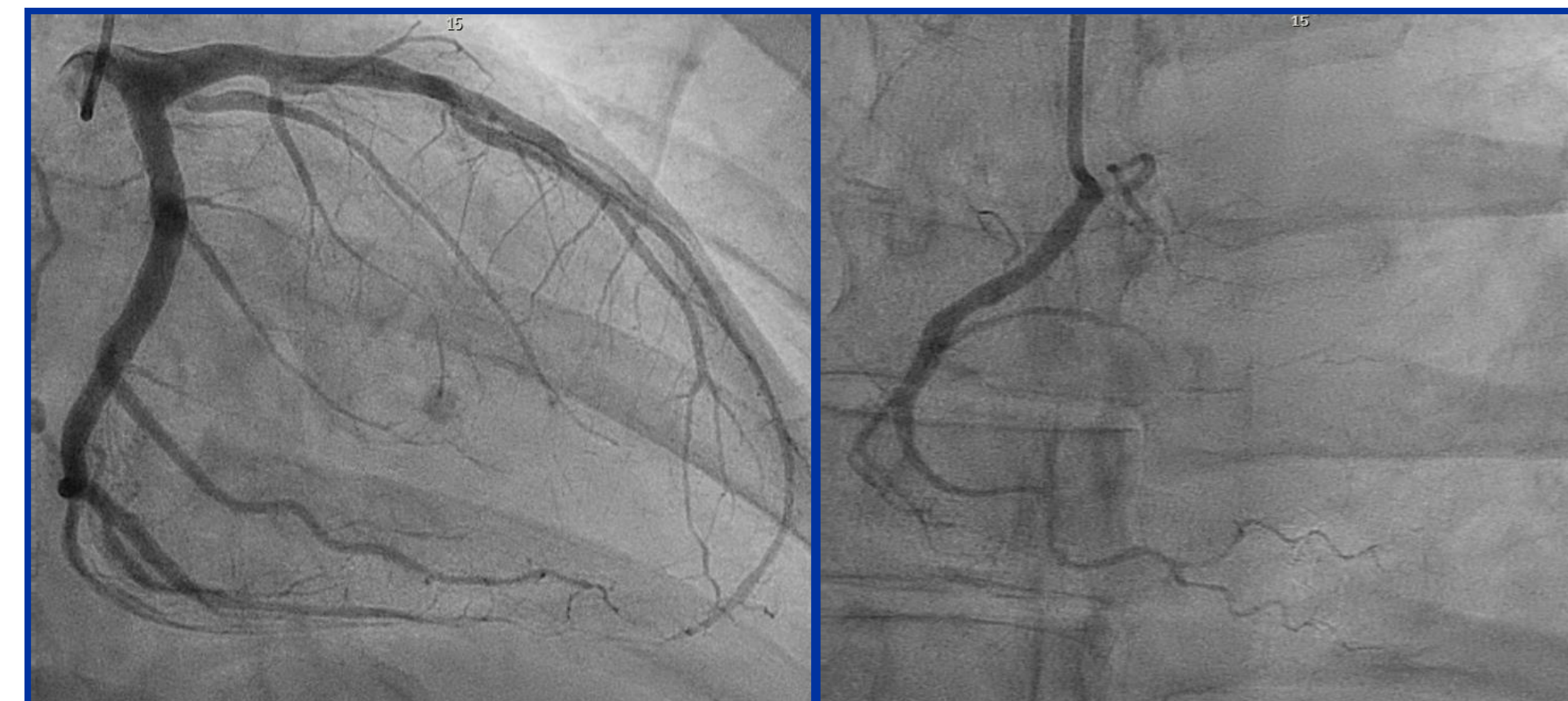**High-sensitivity Troponin T:** 14 ng/L > 26 ng/L

**Transthoracic echocardiogram:** LVEF > 55%, no regional wall motion abnormalities

**Coronary angiography:** left-dominant coronary circulation with mild luminal irregularities in the left circumflex, angiographically normal coronaries otherwise



**Fig. 1. Electrocardiogram:** 12-lead ECG obtained shortly after initiation of vancomycin infusion demonstrated 2-millimeter inferior ST elevation with reciprocal ST depression in anterolateral leads.



**Fig. 2. Coronary Angiography.** Catheterization demonstrated a left-dominant system with mild nonobstructive disease and no culprit lesion.

## Discussion

Kounis syndrome is a rare hypersensitivity reaction through cardiac mast cell activation resulting in coronary vasospasm with subsequent myocardial ischemia. Mast cell degranulation may lead to platelet activation, aggregation, and thrombus formation. This phenomenon can occur with or without underlying coronary artery disease.

Diagnosis is supported by troponin elevation and ischemic ECG changes in the setting of a hypersensitivity reaction. Elevated serum histamine and tryptase levels can confirm the diagnosis. Coronary angiography should be performed to rule out plaque rupture.

Management involves withdrawal of the causative agent and intravenous fluid resuscitation. Antihistamines may blunt the allergic response, while morphine should be avoided due to further release of histamine. Calcium channel blockers can reduce vasospasm, but epinephrine and beta-blockade with unopposed alpha-adrenergic action may potentiate coronary vasospasm. Nitroglycerin may worsen hypotension.

## Conclusion

Kounis Syndrome represents an unusual cause of transient ST elevation which mimics classic ACS. Appropriate and timely recognition of this as a separate entity is of paramount importance, as typical treatments may worsen patient outcomes.

## References

1. Kounis N, Zavras G. Histamine-induced coronary artery spasm: The concept of allergic angina. *The British journal of clinical practice.* 1991;45:121-8.
2. Fassio F, Losappio L, Antolin-Amerigo D, et al., Kounis syndrome: a concise review with focus on management. *European Journal of Internal Medicine.* 2016;30:7-10.
3. Abdelghany M, Subedi R, Shah S, et al. Kounis syndrome: a review article on epidemiology, diagnostic findings, management and complications of allergic acute coronary syndrome. *International Journal of Cardiology.* 2017;232:1-4.
4. Kounis N. Kounis syndrome: an update on epidemiology, pathogenesis, diagnosis and therapeutic management. *Clinical Chemistry and Laboratory Medicine.* 2016;54:1545-1559.