

Objective

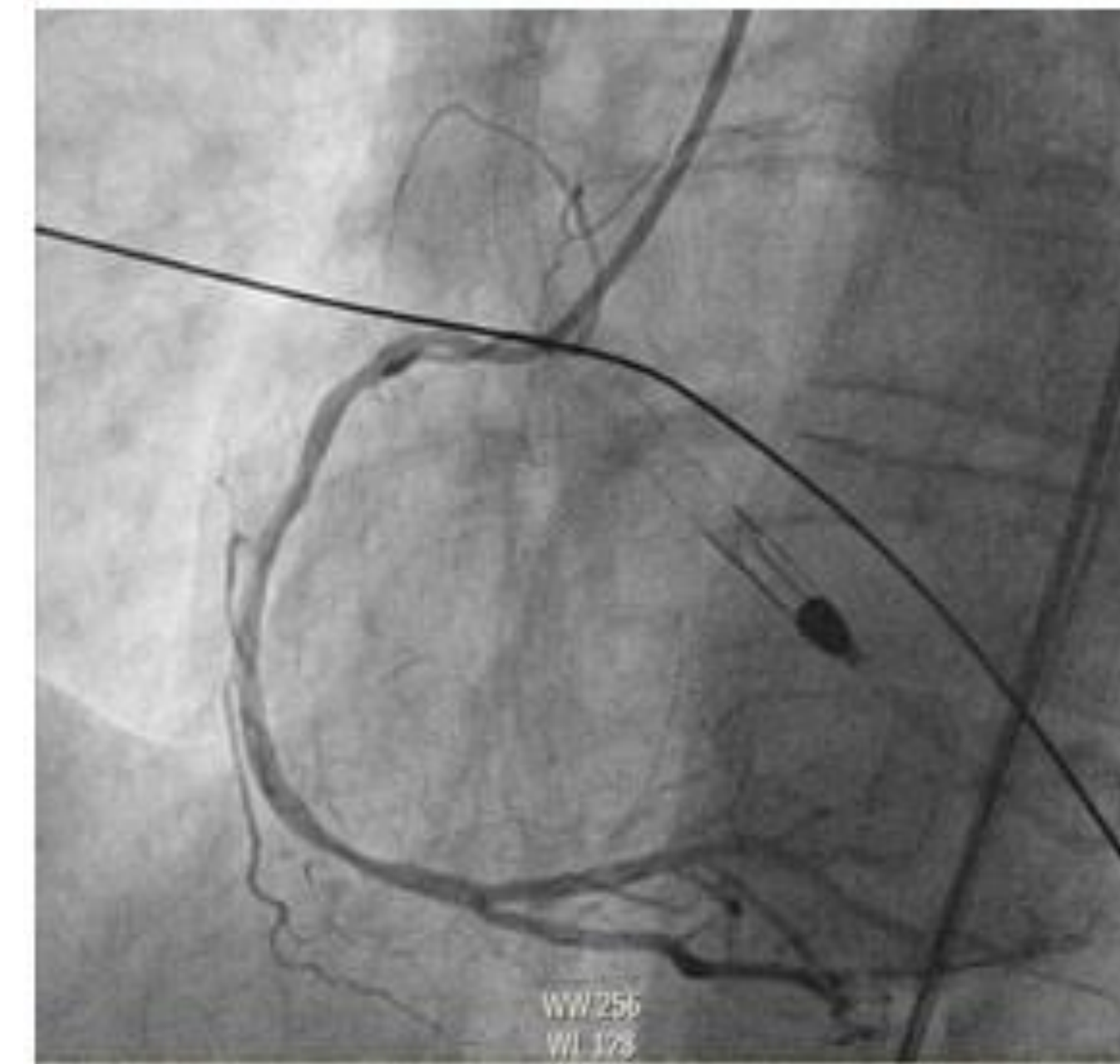
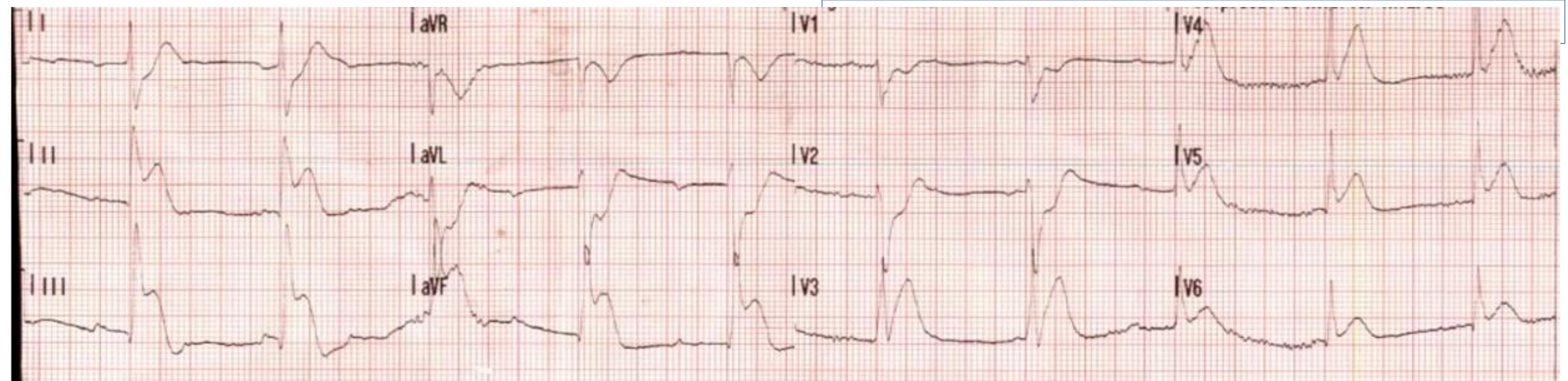
To understand the uncharacteristic presentation of dehydration ST-elevation myocardial infarction (STEMI). To underscore the importance of differentiating dehydration STEMI from the commonly occurring atherosclerotic STEMI, which determines varying treatment.

Introduction

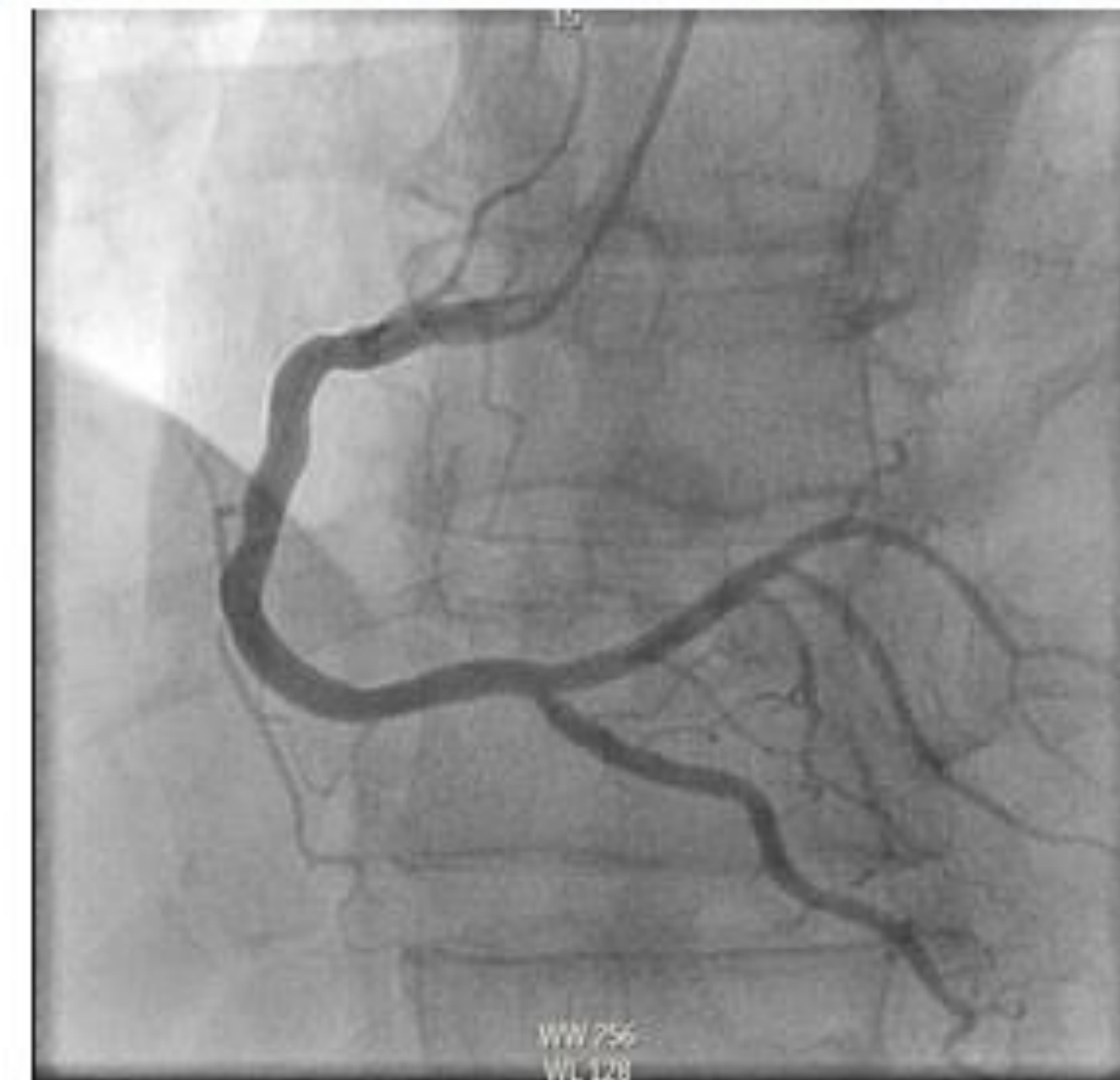Acute ST-elevation myocardial infarction (STEMI) due to hypovolemia/dehydration is an uncommon presentation of Acute Coronary Syndrome (ACS). While many cases of STEMI are treated through percutaneous coronary intervention (PCI), dehydration STEMI is treated by rehydrating the patient thus decreasing the coronary artery vasospasm. Dehydration STEMI presents in the same manner as atherosclerotic STEMI only distinguished by no apparent atherosclerotic obstruction of the coronary vessels upon surgical examination. Timely identification of dehydration STEMI is important for reducing cardiovascular injury by adjusting the treatment accordingly. We present a unique case of acute STEMI in a severely dehydrated patient that led to coronary vasospasm.

Case Presentation

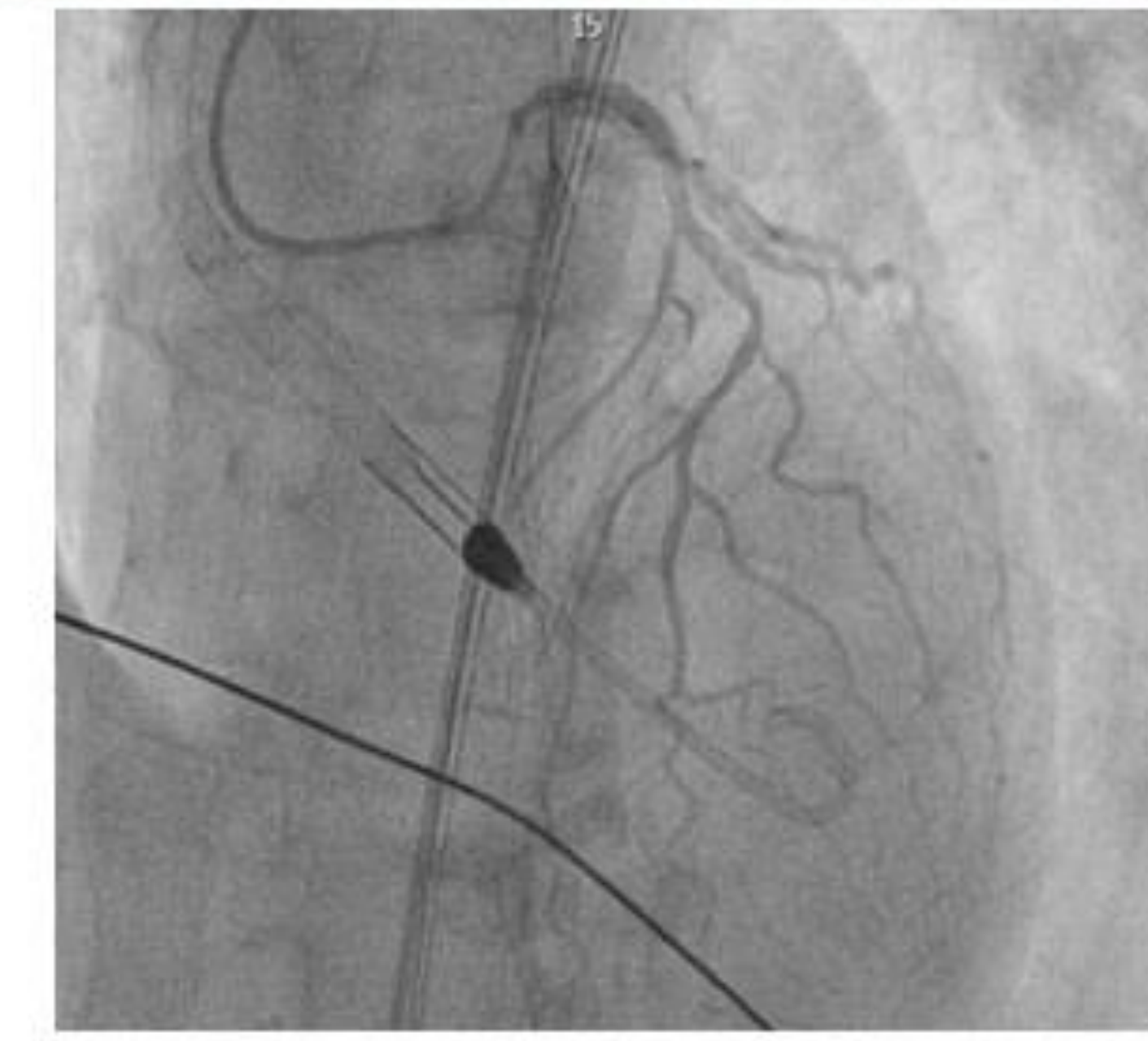
A 57-year-old male with a past medical history of tobacco abuse, gastroesophageal reflux disease, and type 2 diabetes mellitus presented with a syncopal event causing him to drive off into a median. Upon presentation to the ER, EKG showed an inferior ST-segment elevation and an elevated troponin level. He was diagnosed with a STEMI and underwent cardiac catheterization. Impella was placed prior to LHC per NCSI. Cardiac catheterization showed the left circumflex artery with no significant disease, and the obtuse marginal branches angiographically free of disease. The left anterior descending artery showed mild diffuse disease in addition to a focal 20-30% disease in the mid-segment, but diagonal branches were angiographically free of disease. The right coronary artery was noted to have severe ostial disease, but TIMI-3 flow was noted through the entire system. There was also mild diffuse disease in the mid-segment in addition to another 50% focal disease in the distal part. Right heart catheterization was performed which showed low filling pressures and normal PAPI. Echocardiogram showed a normal ejection fraction of 60-65% and normal left ventricular wall motion. Due to TIMI III flow, absence of plaque rupture/erosion, normal wall motion and normal PAPI, we decided against proceeding with any coronary intervention. Patient received aggressive hydration in the next few days. Repeat LHC was performed for re-evaluation that showed resolution of RCA and LAD disease indicative of coronary vasospasm. Patient was discharged on low-dose beta blockers and low-dose aspirin



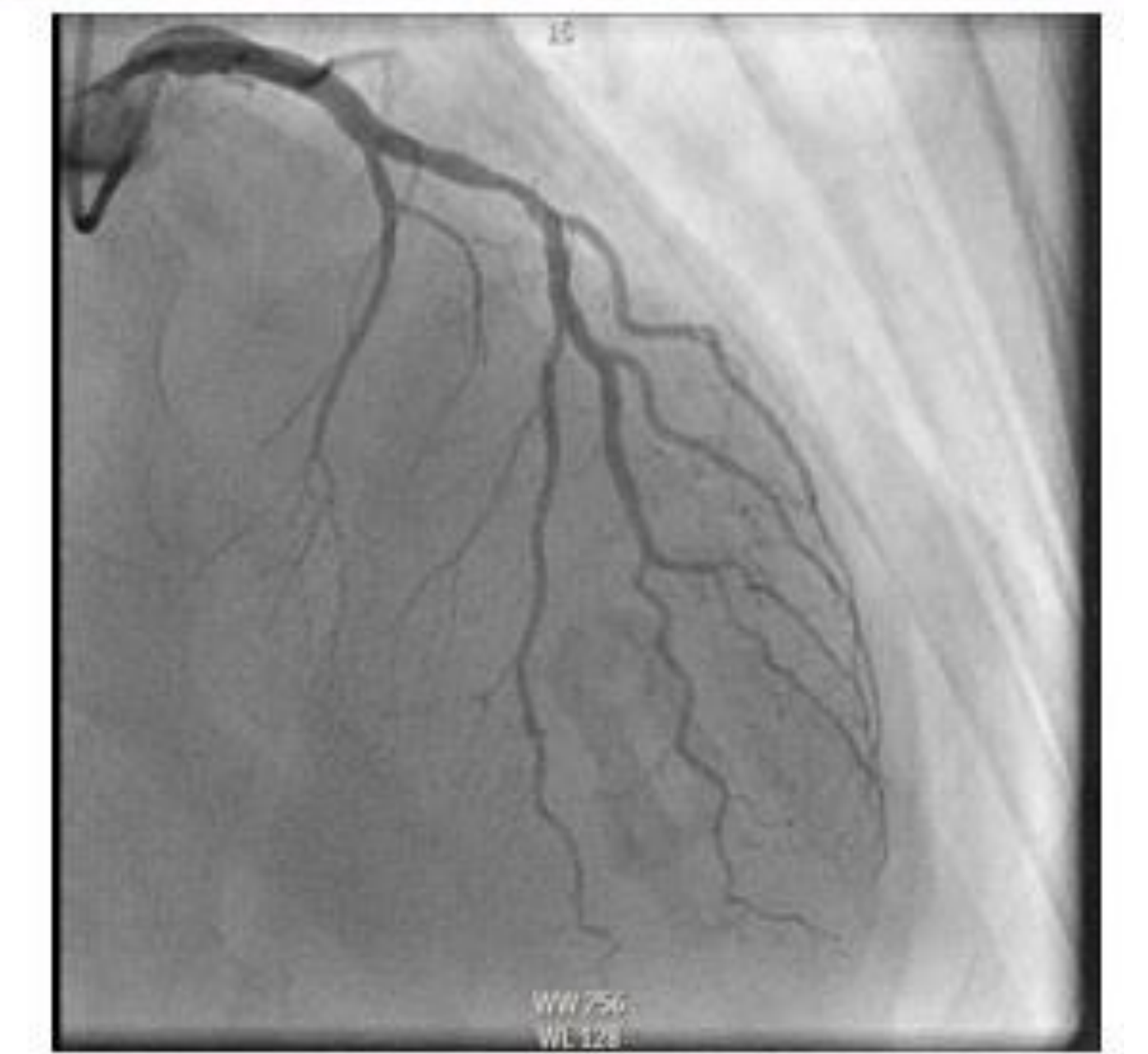RCA on first LHC



RCA on second LHC



LAD on first LHC



LAD on second LHC

Discussion

Acute STEMI due to severe dehydration is an uncommon cause of ACS. Typical presentation of STEMI is caused by an unstable plaque rupture leading to occlusion of the coronary vessels. This leads to the patient experiencing deep pressure chest pain that can radiate to left arm, diaphoresis and dyspnea. However, vaso-occlusion is not the sole cause of myocardial infarction (MI). Previous studies have found incidence of angiographically normal arteries in acute MI to vary between 1.0-8.5%. In patients presenting with acute STEMI in the setting of hypovolemic shock, coronary vasospasm should be considered as a differential.

Conclusions

Although rare, hypovolemia/dehydration can cause a STEMI with angiographically clear coronary arteries from coronary vasospasm. It is important to differentiate this type of STEMI from the STEMI due to atherosclerotic plaque rupture because of the varying treatments. Prompt diagnosis and aggressive hydration can result optimal outcomes.

Contact

Sajjad Haider MD
U of Ky COM,
Bowling Green.
Email: sajjadhaider@uky.edu
Phone: 270-745-1000

References