His Bundle Pacemaker after Orthotropic Heart Transplant

Ethan Fry, DO; Kristin Ellison, MD; Andrew Kolodziej, MD; Sateesh Kesari, MD; Karam Ayoub, MD; Aaron Hesselson, MD
Division of Cardiovascular Medicine, Gill Heart & Vascular Institute, University of Kentucky, Lexington, KY.

Background

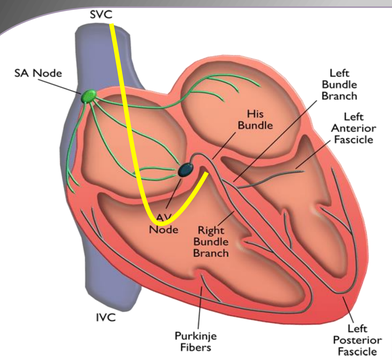

- Standard RV pacing results in ventricular dyssnchrony, impaired contractility, increased mitral regurgitation, decline in ejection fraction, and increased burden of atrial fibrillation. [1-3]
- His bundle pacing (HBP) can result in the activation of the heart through the intrinsic conduction system. When achieved, this avoids the harmful consequences of single ventricular pacing.

Case Report

A 63-year-old male with significant co-morbidities including ischemic cardiomyopathy with an ejection fraction (EF) of < 20% and pulmonary hypertension on continuous infusion of intravenous milrinone, underwent orthotropic heart transplant (OHT) with bi-caval anastomosis.

- Hospital course was complicated by graft biventricular failure and symptomatic bradycardia requiring temporary pacing and atrial fibrillation. Biopsy did not reveal rejection.
- The electrophysiology team was consulted for recurrent sinus node dysfunction and the decision was to proceed with implanting a dual chamber his-bundle permenant pacemaker (HBP).

Case Report (Cont.)

A C315-His non-deflectable sheath was used with the 3830 Medtronic His bundle lead via cephalic vein.

- Mapping of the His bundle was done through unipolar hook up of the pacing lead and electrograms before and after fixation are shown in figures 1A and B. The implanted lead values were threshold 0.75 Volts at 1 millisecond, R wave of 2.8 millivolts, and an impedance of 663 Ohms.
- Pacing from this sight led to beneficial recruit of the right bundle as shown in figure 1C. Atrial lead was subsequently placed.
- Electrocardiograms (ECGs) before and after HBP placement are shown in Fig 2. Patient had baseline right bundle branch block (RBBB) (figure 2A) that narrowed by HBP (figure 2B).

Figure 1a: Electrogram from His lead before lead fixation. 1ACH 1,2 channel showing a far-field atrial (A), His (H) and ventricular (V) deflections.

Figure 1b: Electrogram from the His Bundle lead after lead fixation.

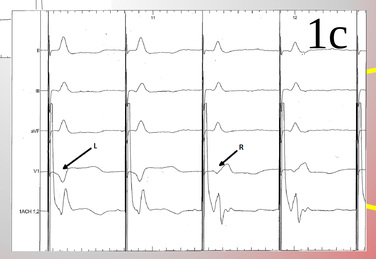

Figure 1c: Electrogram showing selective His bundle pacing with and without correction of underlying right bundle branch block with decreasing pacing thresholds.

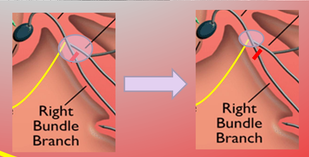

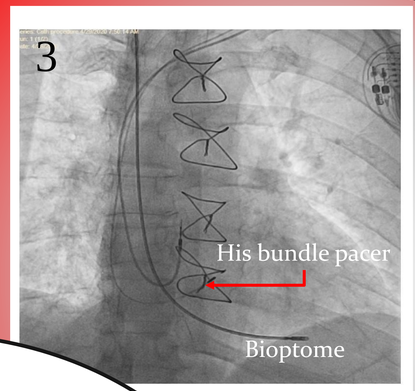

Figure 3: Image at time of Myocardial Biopsy Atrial, His bundle and bioptome are labeled

- He continued to undergo RV endomyocardial biopsies as part of allograft rejection surveillance program without complications, as shown in the fluoroscopic picture in figure 3.

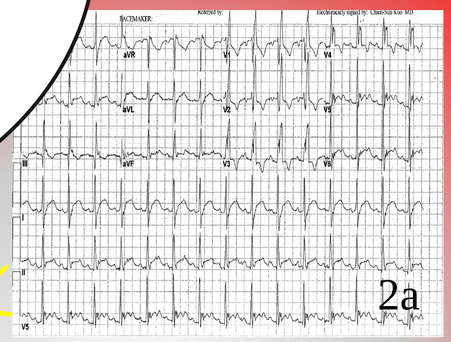

Figure 2a: Baseline ECG with RBBB with QRS duration of 152 msec.

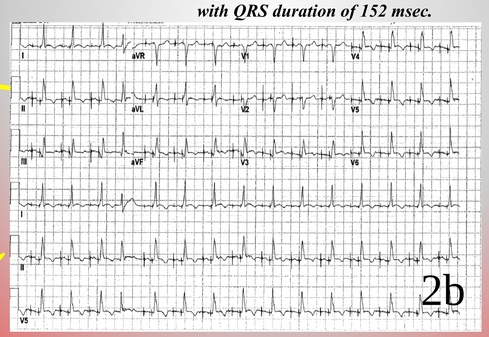

Figure 2b: AV His bundle paced with recruitment of RBBB with QRS duration of 104 ms.

Conclusion

- A dual chamber His bundle pacemaker was safely implanted in an OHT patient
- Dual chamber HBP with RBBB recruitment is possible and potentially beneficial in a transplanted heart with low EF, underlying RBBB, and pulmonary hypertension
- HBP has further benefit in transplanted hearts by leaving the septum available for biopsy

Discussion

Incidence of arrhythmias post OHT is common, Including both tachy and bradyarrhythmias [4].

Indications for permanent pacing after OHT are bimodal with early and late occurrences. [5, 6]

In adults, early implants tend to be for SND. Late implantations, 1-6 months post-transplant, are for both SND and AVB. The bi-caval transplant technique has been associated with decrease PM requirements. [6]

Use of dual chamber HBP in OHT patients is not well described in the literature. In our patient, the standard HBP placement protocol was utilized, as previously described in the literature.

HBP can be utilized to recruit the left or right bundle branches beyond the level of the block within the His bundle [7-9].

His bundle pacing is also an option in patients with low EF and RBBB as seen in Sharma, et al. HBP was associated with improved heart failure outcomes in this population. [9]

In our patient with SND, baseline RBBB, biventricular failure, and pulmonary HTN, HBP was successfully performed. Long term follow up revealed the patient required atrial pacing of 87% in the atrium and near 100% in the ventricle. Thresholds remained stable at 1.65 volts at 0.4 milliseconds.

References

1.Grines, C.L., et al., Functional abnormalities in isolated left bundle branch block. The effect of interventricular asynchrony. Circulation, 1989. 79(4): p. 845-53.

2.Wilkoff, B.L., et al., Dual-chamber pacing or ventricular backup pacing in patients with an implantable defibrillator: the Dual Chamber and VVI Implantable Defibrillator (DAVID) Trial. JAMA, 2002. 288(24): p. 3115-23.

3.Sweeney, M.O., et al., Adverse effect of ventricular pacing on heart failure and atrial fibrillation among patients with normal baseline QRS duration in a clinical trial of pacemaker therapy for sinus node dysfunction. Circulation, 2003. 107(23): p. 2932-7.

4. Anees Thajudeen, et al. Arrhythmias After Heart Transplantation: Mechanisms and Management. J Am Heart Assoc. 2012 Apr; 1(2): e001461.

5.Mallidi, H.R. and M. Bates, Pacemaker Use Following Heart Transplantation. Ochsner J, 2017. 17(1): p. 20-24.

6.Jones, D.G., et al., Permanent pacemaker implantation early and late after heart transplantation: clinical indication, risk factors and prognostic implications. J Heart Lung Transplant, 2011. 30(11): p. 1257-65.

7.Lustgarten, D.L., et al., His-bundle pacing versus biventricular pacing in cardiac resynchronization therapy patients: A crossover design comparison. Heart Rhythm, 2015. 12(7): p. 1548-57.

8.Christopher Cheung, M.B.K.L., MD, FACC His Corrective Pacing or Biventricular Pacing for Cardiac Resynchronization in HF. American College of Cardiology Expert Analysis 09/13/2019.

9. Sharma, P.S., et al., Permanent His Bundle Pacing for Cardiac Resynchronization Therapy in Patients With Heart Failure and Right Bundle Branch Block. Circ Arrhythm Electrophysiol, 2018. 11(9): p. e006613.