Fire in the Hole: Not Your Typical PFO

Natasha Rasool MD, Bashar Al hemyari MD, Jacqueline Dawson Dowe MD, Muhammad Akbar MD

1- University of Kentucky – Bowling Green 2- Medical Center Health

Introduction:

A patent foramen ovale (PFO) is a remnant of fetal circulation characterized by persistent connection between the superior limb of the septum secundum on the right atrial (RA) side and the septum primum on the left atrial (LA) side. PFO is found incidentally in approximately 20-25% of population and is often associated with other cardiac defects such as atrial septal aneurysm (ASA), Eustachian valve[1], and Ebstein anomaly. Most patients are asymptomatic; however, it has been implicated in many clinical scenarios such as cerebrovascular accidents, paradoxical embolism, decompression sickness and Platypnea-orthodeoxia syndrome. Most symptoms occur after development of elevated right-sided cardiac pressures leading to right-to-left blood shunt through the PFO. We present a case of severe hypoxemia due to right-left shunt through a PFO with concomitant prominent Eustachian valve (EV) and ASA.

Case Presentation:

A 39-year-old woman with history of non-ischemic cardiomyopathy, ejection fraction (EF) improved from 20% to 50% with guideline directed medical therapy.

Her other medical conditions include persistent atrial fibrillation, morbid obesity, chronic obstructive pulmonary disease, obstructive sleep apnea.

She presented with worsening shortness of breath, orthopnea and bilateral lower extremity swelling. Physical examination showed distended jugular venous pressure, pulmonary crackles, and +3 bilateral pitting pedal edema.

Initial workup showed bilateral pulmonary venous congestion on chest radiography. A transthoracic echocardiogram (TTE) showed EF 10-15%, severely dilated left ventricle (LV), moderate mitral regurgitation, very severe tricuspid regurgitation (TR), severely dilated right ventricle, flattened interventricular septum, right ventricular systolic pressure 50-60mmHg, with possible right to left inter-atrial shunt.

Hospital Course:

She was started on intravenous diuretics. The following day, she developed acute hypoxemic respiratory failure requiring mechanical ventilation. Pulmonary embolism was ruled out with CT angiogram.

Due to refractory hypoxemia (Partial pressure of oxygen measured 52 mmHg) despite maximum FiO2 supplementation, we performed a transesophageal echocardiogram (TEE) that showed an ASA and prominent EV. Color doppler showed a wide-open TR directing blood flow toward a large PFO (grade 3) causing persistent right-left shunt. These findings suggest Eisenmenger physiology due to pulmonary hypertension from a combination of left sided heart failure (WHO group II) and pulmonology pathology (WHO group III).

The patient was subsequently started on inhaled nitric oxide infusion which improved her oxygen saturation significantly. Despite a prolonged hospital course, she was successfully extubated after aggressive diuresis. The patient was discharged to a nursing home and remained stable at a 3 month follow up.

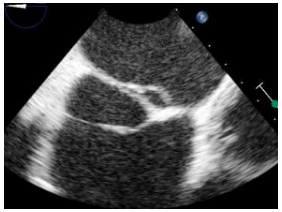

PFO with Aneurysmal atrial septum

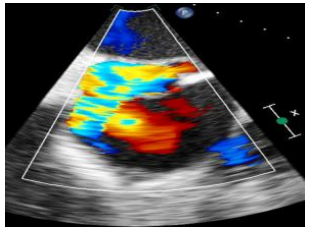

Prominent Eustachian Valve

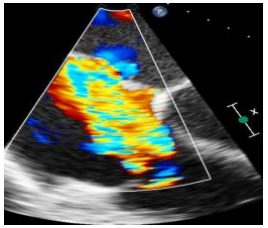

Torrential TR directing blood flow to PFO

Discussion:

PFO is a flap-like structure between atria which does not allow significant left-right shunt under normal cardiac pressures. A transient right-to-left gradient occurs in normal individuals during early ventricular systole and with Valsalva maneuver such as coughing. Eisenmenger syndrome occurs due to progressive increase in pulmonary artery pressure from various etiologies leading to persistent right-left shunt. Refractory hypoxemia prompts further workup to rule out intracardiac shunting. We present a unique case of PFO with right-left shunt in addition to a prominent EV which further directs blood flow from IVC to inter-atrial septum, preventing spontaneous closure of foramen ovale[2].

Management of such complex cases is challenging. Multidisciplinary team including cardiology, pulmonology and cardiothoracic surgery should be involved. The mainstay of treatment is by maintaining euvolemia and alleviating pulmonary hypertension to decrease right-left shunt[3]. PFO closure is not recommended once Eisenmenger physiology develops.[4] Heart and lung transplantation might be needed in refractory cases.

References

[1] Rigatelli G, Dell'avvocata F, Braggion G, Giordan M, Chinaglia M, Cardaioli P. Persistent venous valves correlate with increased shunt and multiple preceding cryptogenic embolic events in patients with patent foramen ovale: an intracardiac echocardiogra

[2] Cai, Q, Ahmad, M. Eustachian valve, interatrial shunt, and paradoxical embolism. *Echocardiography*. 2020; 37: 939– 944. https://doi-org.ezproxy.uky.edu/10.1111/echo.14682

[3] Heidi M Conolly. Management of Eisenmenger Syndrome. In: UpToDate, Post, TW(Ed), UpToDate, Waltham,MA, 2020

[4] Stout KK, Daniels CJ, Aboulhosn JA, et al. 2018 AHA/ACC Guideline for the Management of Adults With Congenital Heart Disease: A Report of the American College of Cardiology/American Heart Association Task Force on Clinical Practice Guidelines [published correction appears in J Am Coll Cardiol. 2019 May 14;73(18):2361-2362]. *J Am Coll Cardiol*. 2019;73(12):e81-e192. doi:10.1016/j.jacc.2018.08.1029