# Is Cardiac Resynchronization Therapy beneficial in patients with exercise induced LBBB and heart failure

Bashar Al hemyari MD, Megan Smith DO, Mohammed Kazimuddin MD, Jacqueline Dawson Dowe MD

1- University of Kentucky – Bowling Green 2- Medical Center Health

## Introduction

- ✓ Cardiac resynchronization therapy (CRT) is a cardiac pacing device used in patients with severe left ventricular (LV) dysfunction that provides simultaneous biventricular electrical activation. CRT leads to improvement of heart failure symptoms, reducing hospital admissions and mortality in patients with moderate to severe heart failure [1].
- ✓ Transient left bundle branch block (LBBB) has been reported following certain conditions such as cardiac blunt trauma, hyperkalemia, myocardial infarction (MI) or exercise induced LBBB. Exercise-induced LBBB occurs in approximately 0.5% of patients undergoing an exercise stress test, which appears to have a higher mortality rates and more cardiac events [2].
- ✓ We describe a case of heart failure with reduced ejection fraction who develops transient LBBB while walking. It's unclear if our patient will benefit from CRT to alleviate heart failure symptoms.

## Case Presentation

- ✓ 49-year-old man with known history of non-ischemic cardiomyopathy, heart failure reduced ejection fraction 15-20%, status post implantable cardiac defibrillator (ICD) is seen in the clinic for follow-up.
- ✓ He reports dyspnea at rest, but denies orthopnea, paroxysmal nocturnal dyspnea, dizziness or chest pain. His symptoms are consistent with NYHA class III.
- ✓ He is compliant with low-sodium diet.
- ✓ Medications: carvedilol 12.5 mg twice daily, Sacubitril/Valsartan 24/26 mg twice daily, spironolactone 25 mg daily, bumetanide 2 mg twice daily, Digoxin 0.125 mcg daily.

## Case Presentation (continuation)

- ✓ His weight is 176 lbs (stable from previous visit 4 weeks ago).
- ✓ Blood pressure 102/72 mmHg, heart rate 62 bpm, oxygen saturation 96% on room air.
- ✓ Physical examination, jugular venous pressure is estimated at 8 cm H2O, lungs are clear to auscultation bilaterally, point of maximal impulse is displaced laterally, normal S1 and S2, soft holosystolic murmur III/IV heard at the left sternal border, but no gallops or heave. There is a trace bilateral lower extremity swelling.
- ✓ Echocardiogram shows severe global hypokinesia, severe LV dysfunction with ejection fraction 15-20%, moderate mitral regurgitation, mild-moderate tricuspid regurgitation, all of which are unchanged from last study done three months ago.
- ✓ His baseline Electrocardiogram (EKG) shows normal sinus rhythm with nonspecific T-wave changes in the lateral leads. The patient performed a 6-minute walking test with distance < 300 meters. Immediately after walking, a repeat EKG showed a new LBBB which disappeared 5 minutes after rest.
- ✓ ICD interrogation showed no evidence of arrhythmias.

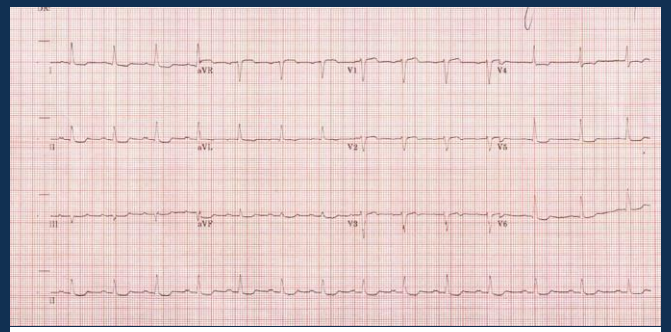

Image 1: Baseline EKG at rest showing normal sinus rhythm with non-specific ST changes in lateral leads

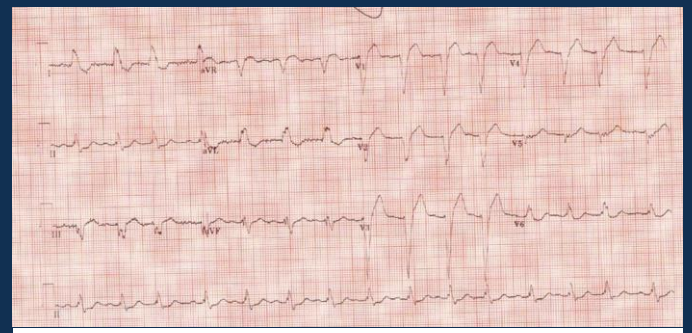

Image 2: EKG during exercise showing left bundle branch block.

## Discussion

- ✓ Ventricular dyssynchrony due to LBBB is associated with increased cardiovascular mortality, that is more pronounced in the presence of heart failure [3]. Several studies have reported that LBBB is an independent risk factor for mortality in patients with HF and is associated with increased all-cause mortality and sudden death at one year [4, 5].
- ✓ CRT is indicated in HF patients with NYHA class II-IV who have LV ejection fraction of < 35%, persistent LBBB with QRS duration of ≥ 120 ms (especially when is more than 150 ms) while receiving guideline-directed medical therapy (GDMT).
- ✓ Our patient develops LBBB while walking for short distance. It's unknown how long throughout the day he's conducting in a LBBB fashion, which might be contributing to his symptoms. In unclear if such a patient would benefit from CRT to help synchronize the ventricles and alleviate his symptoms. More studies are warranted to determine IF CRT is effective in patients with exercise induced LBBB and heart failure.

## References

1. St John Sutton MG, Plappert T, Abraham WT, Smith AL, DeLurgio DB, Leon AR, et al. Effect of cardiac resynchronization therapy on left ventricular size and function in chronic heart failure. Circulation. 2003;107(15):1985–90
2. Prognostic significance of exercise-induced left bundle-branch block. JAMA. 1998 Jan 14;279(2):153-6.
3. Left bundle branch block and mortality in patients with acute heart failure syndrome: a substudy of the EFICA cohort. Eur J Heart Fail. 2010 Feb;12(2):156-63. doi: 10.1093/eurjhf/hfp180. Epub 2009 Dec 21.
4. McCullough PA, Hassan SA, Pallekonda V, et al. Bundle branch block patterns, age, renal dysfunction, and heart failure mortality. Int J Cardiol 2005; 102:303.
5. Baldasseroni S, Opasich C, Gorini M, et al. Left bundle-branch block is associated with increased 1-year sudden and total mortality rate in 5517 outpatients with congestive heart failure: a report from the Italian network on congestive heart failure. Am Heart J 2002; 143:398.